



PATIENT

Rosie Nesbit

SPECIES

Canine

BREED

Dachshund

SEX

Female Spayed

AGE

11 years

WEIGHT

12.6lbs

INTERPRETED BY

Maggie Machen
Lamy, DVM, DACVIM
(Cardiology)

IMAGING PERFORMED BY

Jenna Walsh, CVT

HOSPITAL NAME

VCA Westmoreland
Animal Hospital

REFERRING VET

Dr. Sullivan

INVOICE

23973

DATE

5/2/22

PRESENTING CLINICAL SIGNS

History: 4/25: P presented for progression of clinical signs: polyphagia, PU/PD, distended abdomen, panting. P also seems confused at times. P has been excessively panting and now the tongue is turning purple at times. P is anxious and has a grade 2/6, systolic, left sided heart murmur. Today it is muffled. P is very painful in the abdomen and the abdomen is distended and pendulous but also very taught. LDDS was inconclusive for Cushings disease. Elevated liver enzymes, platelets and dilute urine. PE 4/20: Abdominal pain, Pendulous abdomen, Polyuria and polydipsia, Seborrhea, Overweight, Weight gain, Hepatomegaly, heart murmur 2/6, Nuclear sclerosis, Chronic dental disease, subdermal mass right shoulder, Anal gland disease (historical), Otitis externa, Aural debris, Comedones
 Abnormal PE/Chem/CBC/UA Results: BP- 143/405/114 Attached Chemistry- globulin-3.7, ALKP-849, BUN/CREAT RATIO 41, CALCIUM 11.7, TRIGLYCERIDE 296, AMYLASE 1126, PrecisionPSL 254 Dex suppression- normal

ELECTROCARDIOGRAPHIC FINDINGS *Note: Single lead ECGs are evaluated as a rhythm strip. Morphology/MEA cannot be definitively commented on.

A single lead ECG is available; 50mm/s, 5mm/mV. The average heart rate is 110bpm (range 60-166bpm). The rhythm is sinus in origin, with a p for every QRS complex and vice versa. The P and QRS morphologies are positive. No ectopic beats, pauses or dysrhythmias observed. ECG diagnosis: Suspect profound respiratory sinus arrhythmia.

ECHOCARDIOGRAM FINDINGS

2D, m-mode, color flow and doppler imaging is available. Mild diffuse thickening of mitral valve leaflets with no prolapse into the left atrial lumen. Mild eccentric mitral regurgitation with mild left atrial dilation. Normal MR velocity. Normal LV diameter with adequate myocardial function. The tricuspid valve appears normal with trace tricuspid regurgitation. Normal velocity. Normal right atrial and ventricular diameter and morphology indicating no overt evidence of pulmonary arterial hypertension. The pulmonic and aortic valves are normal in morphology and mobility. Normal pulmonic and aortic outflow velocities with laminar flow. No obvious aortic or pulmonic insufficiency. No pericardial or pleural effusion noted. No obvious cardiac masses.

CARDIAC CHART

CANINE CARDIAC PARAMETERS	MR VMAX (m/s)	TR VMAX (m/s)	LA/AO (Boon method)	LA/AO (Heart Base; Swe)	FS (%)	EF (%)	EPSS (cm)
NORMAL PARAMETER	4.5-5.5	<2.7	1.3	<1.6	28-40	40-100	<0.6
PATIENT	4.9	2.0	1.2	1.2	48	82	NM
CANINE CARDIAC PARAMETERS	HR (BPM)	AV VMAX (m/s)	PV MAX (m/s)	BODY WEIGHT (kg)	LA 2D short axis Base view (cm)	LVIDd Avg; 2D and m-mode short axis (cm)	LVIDs Avg; 2D and m-mode short axis (cm)
NORMAL PARAMETER	50-100	0.7-1.7	0.7-1.6	BELOW	BELOW	BELOW	BELOW
PATIENT	130	1.8	1.0	5.3	1.6	2.0	1.0
*Normal chamber parameters expressed as a mean value (SD)				3	1.27 (5.3)	2.46 (2.46)	1.36 (5.5)



PATIENT

Rosie Nesbit

SPECIES

Canine

BREED

Dachshund

SEX

Female Spayed

AGE

11 years

WEIGHT

12.6lbs

INTERPRETED BY

Maggie Machen
 Lamy, DVM, DACVIM
 (Cardiology)

IMAGING PERFORMED BY

Jenna Walsh, CVT

HOSPITAL NAME

VCA Westmoreland
 Animal Hospital

REFERRING VET

Dr. Sullivan

INVOICE

23973

DATE

5/2/22

BODY WEIGHT DEPENDENT PARAMETERS

Adapted from June Boon, Veterinary Echocardiography, 1998
 Rishniw M and Hollis NE, J Vet Intern Med 2000; 14:429-435
 Hansson et al, Vet Rad and Ultrasound 2002
 Bonagura et al. Echocardiography: principles of interpretation, Vet
 Clin North Am 15:1177, 1995

5	1.40 (4.5)	2.74 (5.2)	1.60 (4.7)
10	1.50 (3.8)	3.27 (3.5)	2.06 (3.1)
15	1.83 (2.0)	3.71 (2.4)	2.43 (2.1)
20	2.02 (1.9)	4.14 (2.2)	2.80 (2.0)
25	2.18 (2.4)	4.48 (2.9)	3.10 (2.5)
30	2.33 (3.3)	4.83 (3.9)	3.39 (3.4)
35	2.48 (4.3)	5.17 (5.0)	3.69 (4.5)
40	2.62 (5.2)	5.48 (6.1)	3.96 (5.4)
50	2.88 (7.1)	6.07 (8.3)	4.46 (7.4)

INTERPRETATION OF THE FINDINGS & FURTHER RECOMMENDATIONS

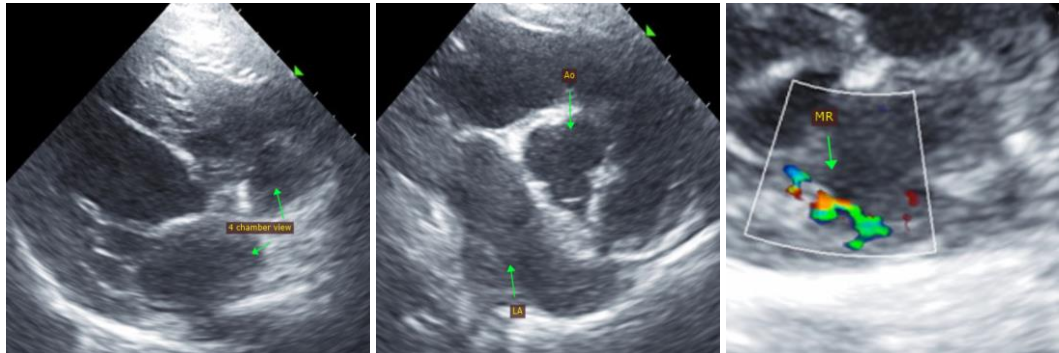
Chronic degenerative valve disease causing mild mitral and trace tricuspid regurgitation. Lack of significant left atrial enlargement indicates the current risk for complication is low. No concurrent issues such as pulmonary hypertension are noted in this study. The ECG is unremarkable with a respiratory sinus arrhythmia. This is likely reflective of high vagal tone, secondary to systemic illnesses.

These findings would suggest abdominal distention and other clinical signs are certainly noncardiac in origin. No cardiac medications are clearly indicated. Assessment of progression in the future will help predict long term prognosis, which is highly variable at this stage (B1). Omega fatty acid supplementation and mild salt restriction may be of some long-term benefit. Monitor for development of a cough, labored breathing, exercise intolerance or collapse episodes.

Anesthetic risk is considered mild if needed. Cardiac protective drug choices (opioid/benzodiazepine premedication, propofol or alfaxalone induction, isoflurane gas) are recommended. Pre-oxygenate for 5-10 minutes prior to induction. Monitor for arrhythmias, hypotension, and hypoxia both intra and post-operatively and intervene as necessary. Mild IV fluid restriction is recommended to avoid fluid overload. Avoid heart rate stimulating drugs such as atropine unless clinically indicated.

Recommend conservative monitoring with a recheck echocardiogram in 6 months, sooner if any development of clinical signs.

IMAGES





PATIENT

Rosie Nesbit

SPECIES

Canine

BREED

Dachshund

SEX

Female Spayed

AGE

11 years

WEIGHT

12.6lbs

INTERPRETED BY

Maggie Machen
Lamy, DVM, DACVIM
(Cardiology)

IMAGING PERFORMED BY

Jenna Walsh, CVT

HOSPITAL NAME

VCA Westmoreland
Animal Hospital

REFERRING VET

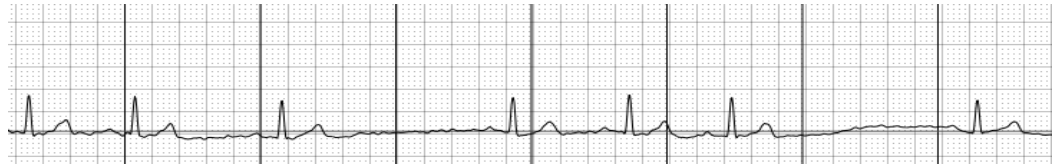
Dr. Sullivan

INVOICE

23973

DATE

5/2/22



The information and recommendations provided are based on the images presented by the referring veterinarian. No evaluation can be communicated regarding pathology that was not visible in the image/video clips provided.

Thank you for this referral. This report was generated using transcription software, and minor dictation errors may be present. If the clinical or image interpretation does not parallel your findings or if I can be of any further assistance, please contact me.

Maggie Machen Lamy, DVM
Diplomate of the American College of Veterinary Internal Medicine (Cardiology)
info@sonopath.com